Tooth Injuries
(Fracture, Luxation, Avulsion)

A tooth consists of the root and the crown. The yellowish, softer dentin is covered by enamel to form the crown. The crown is the visible white part of the tooth. The tooth is attached to the tooth socket by small ligaments. The pulp of the tooth contains the nerves and blood vessels. These are found in the pulp chamber and root canals.

THREE MAIN TOOTH INJURIES ARE:

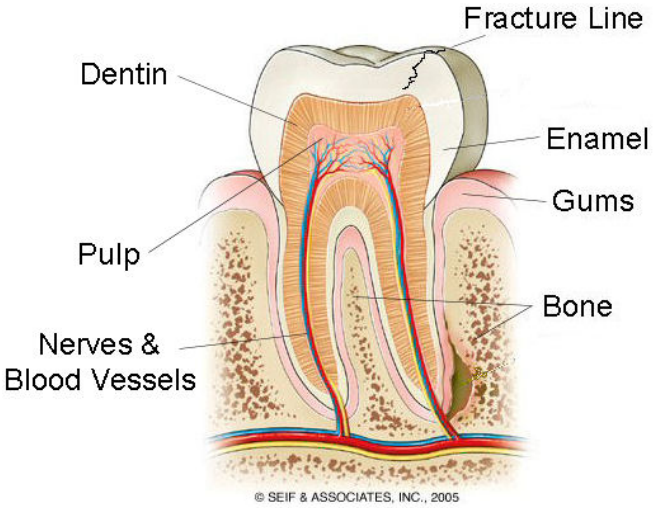

- A **fracture** usually splits the tooth into two or more parts; one attached to the socket and one or more free. A fracture may be classified as a root fracture, broken tooth (*crown fracture*), or chipped tooth. Fractures may also be broken down into types: crown, crown-root, or root. Sometimes they are also broken down into *simple* (no pulp involvement) or *complex* (pulp involvement). A crown fracture may involve the pulp. Tooth fracture may cause problems ranging from *cosmetic defects* (the look of the tooth) to tooth death. If the pulp is involved, this may be more serious than the amount of the tooth affected. Pulp involvement can be noticed by a bleeding site or a pink or red dot in the middle of the dentin. Pulp exposure can be very painful, and limiting nerve exposure to air, *saliva* (fluid in the mouth), temperature changes, and the tongue will decrease the pain.
- *A **luxation*** (dislocation) shifts the tooth position at the level of the root but does not remove it from the socket. There are different types or classes of luxations. The "extruded tooth" appears longer than the surrounding teeth, and a "laterally displaced tooth" is positioned ahead of or behind the normal tooth row. With either injury, the tooth should be firmly grasped with a gloved hand and moved into its normal position. If the procedure is too difficult or too painful, the tooth should be left as is for a dentist to reposition. An "intruded tooth" is pushed into the gum and appears shorter than the surrounding teeth. **Do not** attempt to reposition a dislocated tooth.
- *An **avulsion*** (forced removal by accident or surgery) removes the entire tooth from its socket. The best outcomes require *reimplantation* (putting the tooth back in) within 30 minutes. After 2 hours, the chances of saving the tooth are small. Every effort should be made to locate and protect the lost tooth. The tooth will often still be in the mouth, but if it cannot be located, check clothing, and the surrounding area. If dirty, the tooth should be gently cleaned with water or *saline* (salty water). It should be handled only on its enamel surface, and the root should be protected from further injury(*trauma*). If the injured person is awake, the tooth should be put back in its socket. As the tooth is positioned, the root will usually "click" into place.

TREATMENT

- In an emergency, the root canal can be sealed by covering the nerve with a drop of a "super glue" or cyanoacrylate. The use of cyanoacrylate has not been approved by the US Food and Drug Administration. This is called an off-label use. However, cyanoacrylate is currently used in dentistry for similar purposes.
- Gently biting into gauze or a towel will help control the bleeding. An exposed nerve requires dental exam and care, but an immediate referral is not needed if the pain is controlled.
- Cover exposed dentin with a layer of zinc oxide or calcium hydroxide paste (Dycal) if it is available.
- Tooth fragments should be handled on their enamel surfaces, saved, and sent to the dental office with the injured person. (Follow the guidelines under "Avulsion," above.) The small chips of a minor fracture are often lost but are worth saving and sending with the injured person if they can be found.
- Minor fractures involve only the enamel and usually do not require immediate dental treatment. A tooth can

also be “loosened” by injury with no visible fracture or displacement. This injury should be referred to a dentist for radiologic (*x-ray*) evaluation to look for tooth fractures below the gum line.
- Only take over-the-counter or prescription medicines for pain, discomfort, or fever as directed by your caregiver.
- If you were given antibiotics, finish all of them as directed.
- Avoid eating solid foods and see a dentist within 24 hours.

COMPLICATIONS:
- Tooth loss.
- Cosmetic deformity.
- Infection.

PREVENTION
- Most dental and similar injuries can be prevented or lessened by the use of a mouth guard. These should be worn in all contact sports. Team physicians and dentists should encourage the use of mouth guards in any sport with a potential for mouth injury.
- Mouth guards can also prevent concussions in contact and non-contact sports.

SEEK MEDICAL CARE IF:
- Pain is becoming worse rather than better, or if pain is uncontrolled with medications.
- You have increased swelling or redness in your face near the fractured tooth.

Document Released: 09/14/2005 Document Re-Released: 01/09/2011
ExitCare® Patient Information ©2011 ExitCare, LLC.